


CASE REPORT

# Transitioning from the dental chair to the bronchoscopy table: a rare complication of a root canal procedure

Sara Hussain<sup>1\*</sup> , Goran Nadir Salih<sup>2</sup>, Majed Rafik Mohammadih<sup>1</sup>, Michael George Jalal<sup>1</sup>, Firas AlNajjar<sup>1</sup>

## ABSTRACT

**Background:** Dental needle aspiration is a rare complication of oral procedures given the advances in medical technology. Aspirations in general may also be asymptomatic, apart from the possible remote history of upper airway irritation at the time of induction. Clinicians should take a detailed history and examination, along with appropriate diagnostic imaging before discharging these patients from the emergency department.

**Case Presentation:** A young patient presented with an acute complaint of pain and coughing postdental procedure. On arrival at the emergency department, she was vitally and clinically stable, without signs of respiratory distress. There were no complaints reported apart from minor throat pain. Imaging done in the emergency department revealed the presence of a 32 mm needle in the distal airway. She underwent an emergency flexible bronchoscopy, and the foreign body was removed under direct visualization. The patient remained stable throughout the procedure and had an uneventful stay until discharge.

**Conclusion:** While needle aspiration is a relatively uncommon occurrence, its early detection is always critical before further damage to local structures can occur. Regardless of presentation and symptoms, basic imaging is mandatory before the disposition is decided.

**Keywords:** Dental instrument aspiration, foreign body aspiration, bronchoscopy, aspiration, emergency, pulmonology.

## Introduction

Foreign body aspiration is a common presenting complaint in the emergency department. Patients with aspiration may have an initial period of coughing and gagging with occasional persistent discomfort. If removal is delayed, the area around the foreign body can become a nidus for infection and inflammation [1]. This may become a significant cause of morbidity and mortality in extremes of age or those with other medical comorbidities [2]. It can also potentially make the removal process considerably more difficult.

airway obstruction, no stridor, drooling, or hoarseness of voice. Lower airway examination was also unremarkable with good air entry bilaterally and no added sounds such as wheezes, rales, or rhonchi were appreciated on auscultation.

Past medical history and surgical were unremarkable with regards to her current presentation, total thyroidectomy for a benign goiter, hyperprolactinemia, and other minor surgical procedures.

## Case Presentation

A 29-year-old female patient presented with an acute episode of coughing post root canal surgery in an outpatient clinic environment that occurred two and a half hours before presenting to the emergency department. On arrival, the main complaint was irritation and pain in the throat without respiratory distress or vital sign abnormalities. There were no signs of upper

**Correspondence to:** Sara Hussain

\*Emergency Department, Rashid Hospital, Dubai Academic Health Corporation, Dubai, United Arab Emirates.

**Email:** dr.sarahussain@hotmail.com

*Full list of author information is available at the end of the article.*

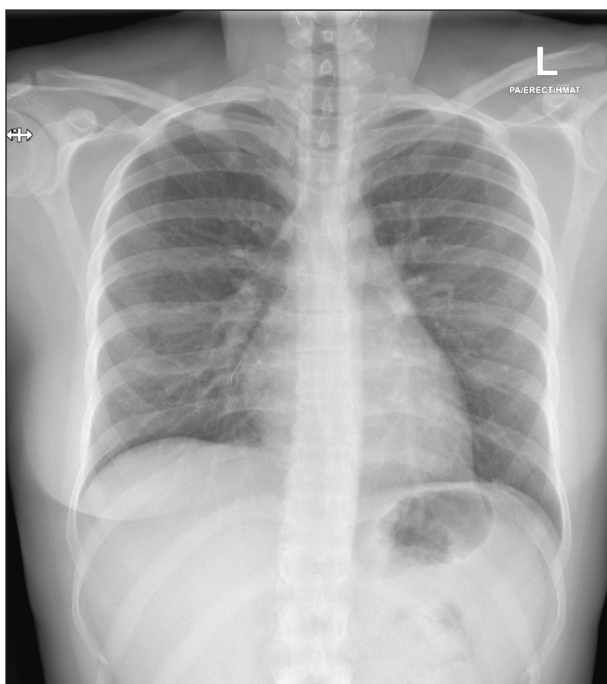
**Received:** 18 May 2023 | **Accepted:** 11 August 2023



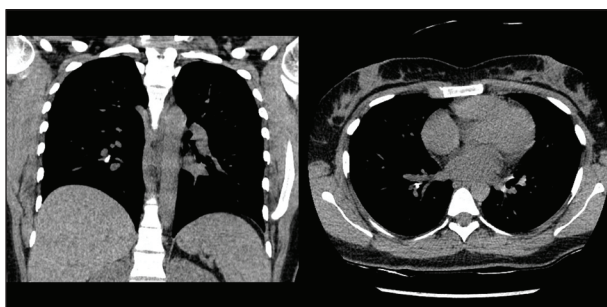
A chest X-ray was done and showed the presence of a needle tip in the airway (Figure 1). Laboratory tests were done and unremarkable. The patient was started on prophylactic cefuroxime and amoxicillin/clavulanic acid by the admitting department.

Computed tomography (CT) scan was performed to confirm the location and type of the foreign body. A 32 mm metallic foreign body was seen stuck in the mucosa of the right lower bronchus, the tip oriented caudally and the base pointing to the lower part of the lung (Figure 2). It was 4 mm at its widest diameter and was radiographically compatible with a dental needle used for root canal procedures. Emergency bronchoscopy was performed under general anesthesia, the needle was identified and removed. Minimal bleeding was noted from the area and the site was irrigated with saline and suctioned.

The patient had an uneventful recovery and postsedation period and was discharged in good medical condition.



**Figure 1.** Chest X-ray PA and lateral view that shows the needle tip in the right lower zone.



**Figure 2.** Chest CT scan in coronal and cross-sectional view that shows the needle in the right lower lobe bronchus, extending to the lateral basal segmental bronchus.

## Discussion

Root canal filling is performed to prevent exposure of the vulnerable tissue to microorganisms and prevent the reentrance of further nutrients to the organisms already present in the canal. The tooth must be appropriately debrided [3]. This is achieved with a variety of instruments and materials subject to the procedure involved. In a 2016 study, 64% of general dentists used rotary endodontic instruments, and 52% used engine-driven nickel titanium. There was also a large percentage that used manual instruments. Any of these apparatuses can potentially be either aspirated or swallowed, both whole or in fragments. Since most practitioners prefer using a combination rather than a single instrument, this can lead to a wider variety of possible aspirates [4]. This being said, accidental foreign body aspiration during a dental procedure is rare, occurring in less than 1%-12% of patient safety incidences [5]. In a 33-year study, only 10 out of 60 cases of foreign bodies in the airway were due to various dental appliances [6]. Similarly, a dental hospital documented two cases of aspiration over a 7-year period [5].

While rare, it is a potentially fatal complication. Therefore, there have been many suggested strategies to decrease the incidence of endodontic aspiration. This includes using a rubber dam with or without a gauze throat pack, and high-velocity evacuation amongst other procedure-specific methods [7].

The aspirate in general can be either organic or inorganic. Organic foreign bodies are more common in the out-of-hospital environment and happen to be usually radiolucent. Inorganic materials such as tooth aspiration, coins, plastic pieces, or iatrogenic complications, are more likely to be radiopaque [2]. Foreign body aspiration is a known complication of intraoral procedures [8].

X-ray is an excellent initial screening tool, but radiolucent objects may not be readily apparent and may need further imaging either in the form of a CT scan or ultrasound. A 45-year-old male presented with a 3-year history of wheezing and repeated chest infections postdental procedure when he had dental impressions taken. Chest X-rays failed to show evidence of aspirate due to radiolucency and the mold was discovered on bronchoscopy [7]. The sensitivity of ultrasound is low in airway foreign bodies, making CT scan a more readily accessible imaging modality in the emergency setting. However, ultrasound can be especially beneficial in the removal process to find potentially hidden radiolucent sub-pleural foreign bodies [2]. Other than localizing the object itself, imaging may occasionally display areas of hyperinflation, obstructive emphysema, or pneumothorax [1]. There might also be signs of infection in case of delayed diagnosis. These secondary changes are especially concerning in pediatrics, where they can be an indicator of worse patient prognosis [9].

Organic foreign bodies can cause more complications due to their absorbent nature, predisposing those patients to infections and a more difficult retrieval process. This can be slightly alleviated by using cryoadhesion. Inorganic foreign bodies cannot be retrieved by this method,

however, and the proceduralist usually relies on grasping tools for an efficient removal process [2].

Rigid bronchoscopy is preferred if the foreign body is harder in consistency and when anticipating more severe bleeding during the removal process. It is also preferred in case of previous failed attempts at removal, prolonged duration from the time of aspiration, and in case of healthy patients without significant medical histories. Flexible bronchoscopy is the more common method used for removal and allows for better visualization of the distal airway [2]. It is therefore in most cases, the initial method used in the retrieval process.

## Conclusion

Often a multidisciplinary team-based approach is preferred in more complicated cases. However, most patients, who present early enough after aspiration, have an excellent recovery and prognosis [2]. Care should be taken to screen for swallowing pathologies before discharge, especially in the cases of organic food material aspiration. Patients should be advised about signs and symptoms of infection or perforation before discharge and follow-up should be advised wherever necessary.

## Acknowledgment

The authors would like to extend their gratitude to Dr Salma Al Rajaby for her help and assistance in this manuscript.

## List of Abbreviations

None.

## Conflict of interests

The authors declare that there is no conflict of interest regarding the publication of this article.

## Funding

None.

## Consent to participate

Written informed consent was obtained from the patient.

## Consent for publication

Written informed consent was obtained from the patient.

## Ethical approval

Ethical approval is not required at our institution to publish an anonymous case report.

## Author details

Sara Hussain<sup>1</sup>, Goran Nadir Salih<sup>2</sup>, Majed Rafik Mohammadi<sup>1</sup>, Michael George Jalal<sup>1</sup>, Firas AlNajjar<sup>1</sup>

1. Emergency Department, Rashid Hospital, Dubai Academic Health Corporation, Dubai, United Arab Emirates
2. Pulmonology Department, Rashid Hospital, Dubai Academic Health Corporation, Dubai, United Arab Emirates

## References

1. Grover S, Bansal A, Singhi SC. Airway foreign body aspiration. *Indian J Pediatr.* 2011 Nov;78(11):1401–3. <https://doi.org/10.1007/s12098-011-0488-8>
2. Bajaj D, Sachdeva A, Deepak D. Foreign body aspiration. *J Thorac Dis.* 2021 Aug;13(8):5159–75. <https://doi.org/10.21037/jtd.2020.03.94>
3. Carrotte P. Endodontics: part 8. Filling the root canal system. *Br Dent J.* 2004;197(11):667–72. <https://doi.org/10.1038/sj.bdj.4811855>
4. Eleazer PD, Gilbert GH, Funkhouser E, Reams GJ, Law AS, Benjamin PL, et al. Techniques and materials used by general dentists during endodontic treatment procedures: findings from the national dental practice-based research network. *J Am Dent Assoc.* 2016;147(1):19–27.
5. Huh J, Lee N, Kim KY, Jung S, Cha J, Kim KD, et al. Foreign body aspiration and ingestion in dental clinic: a seven-year retrospective study. *J Dent Anesth Pain Med.* 2022;22(3):187–95. <https://doi.org/10.17245/jdapm.2022.22.3.187>
6. Limper AH, Prakash UB. Tracheobronchial foreign bodies in adults. *Ann Intern Med.* 1990;112(8):604–9. <https://doi.org/10.7326/0003-4819-112-8-604>
7. Cameron SM, Whitlock WL, Tabor MS. Foreign body aspiration in dentistry: a review. *J Am Dent Assoc.* 1996;127(8):1224–9.
8. Hou R, Zhou H, Hu K, Ding Y, Yang X, Xu G, et al. Thorough documentation of the accidental aspiration and ingestion of foreign objects during dental procedure is necessary: review and analysis of 617 cases. *Head Face Med.* 2016 Jul 22;12(1):23. <https://doi.org/10.1186/s13005-016-0120-2>
9. Sjogren PP, Mills TJ, Pollak AD, Muntz HR, Meier JD, Grimmer JF. Predictors of complicated airway foreign body extraction. *Laryngoscope.* 2018 Feb;128(2):490–5. <https://doi.org/10.1002/lary.26814>