

CASE REPORT

Spontaneous vertebral artery stenosis, dissection, and cerebellar infarction in a man while playing bowling

Waseem Hassan¹, Asif Naveed¹

ABSTRACT

Background: An increased incidence of vertebral artery dissection has recently become a recognized cause of acute stroke for about 1/5 of strokes in young patients.

Case Presentation: A male in his 30s presented to the emergency department with a sudden onset of severe vertigo, vomiting, and dizziness while he was playing bowling. The symptoms started when he suddenly twisted his neck while throwing the ball toward pins. Initial diagnosis of central vertigo led to performing plain CT head and CT head angiogram, which demonstrated non-occlusive extradural left vertebral artery dissection. Following CT scans, an MRI head, and MRA head and neck were performed which confirmed the CT diagnosis and also showed left posterior inferior cerebellar artery territory infarcts with micro hemorrhages. The patient was started on dual antiplatelet medications which were continued for 6 months with a follow-up MRI/MRA scan of the head and neck.

Conclusion: This appears to be a unique case where sudden twisting of the neck possibly resulted in vertebral artery dissection and cerebellar infarction. Hence, it is vital to be aware of sports-related presentations resulting in sudden neck movements and tears in the vertebral artery causing dissection.

Keywords: Posterior circulation stroke, vertigo, posterior inferior cerebellar artery infarction.

Introduction

Vertebral artery dissection has recently become a recognized cause of acute stroke in younger patients [1,2]. In the younger population, there is an increased incidence of dissection of the internal carotid and vertebral arteries in the neck, which accounts for about 1/5 of strokes in young patients [2,3]. There is little evidence to suggest if there is a direct correlation with any particular sports causing vertebral artery dissection. However, a case report reported a carotid artery dissection in long-distance runners [4]. Sports-related cervical artery dissection in professional golf players and scuba divers has been published in research in the past [4,5].

However, no or limited research mentioning vertebral artery dissection connected to recreational sports like bowling has been published. A thorough review of the published research showed that it is relatively common to present with vertebral artery dissection after trauma [6–8]. We present a unique case of a sudden onset spontaneous vertebral artery dissection and posterior inferior cerebellar infarction.

Case Presentation

A fit and healthy young gentleman was presented to the emergency department with sudden onset severe dizziness, vertigo, and vomiting while he was throwing a ball toward pins and playing bowling with his friends. The patient did not suffer from any trauma to the head or neck. The symptoms of vertigo were severe and persistent since the onset. An initial working diagnosis of central vertigo was established in the emergency department. On examination, the patient was noted to have no airway, breathing, or circulation concerns. A thorough neurological examination showed a Glasgow coma score of 15 with normal power, reflexes, and tone in all the limbs. Eye movements and cranial nerves examination were not possible due to severe vertigo and inability to open his eyes. The patient was noted to have positive

Correspondence to: Waseem Hassan

*Walsall Healthcare NHS Trust, Walsall, UK.

Email: hassan_586@hotmail.com

Full list of author information is available at the end of the article.

Received: 6 January 2024 | **Accepted:** 7 February 2024

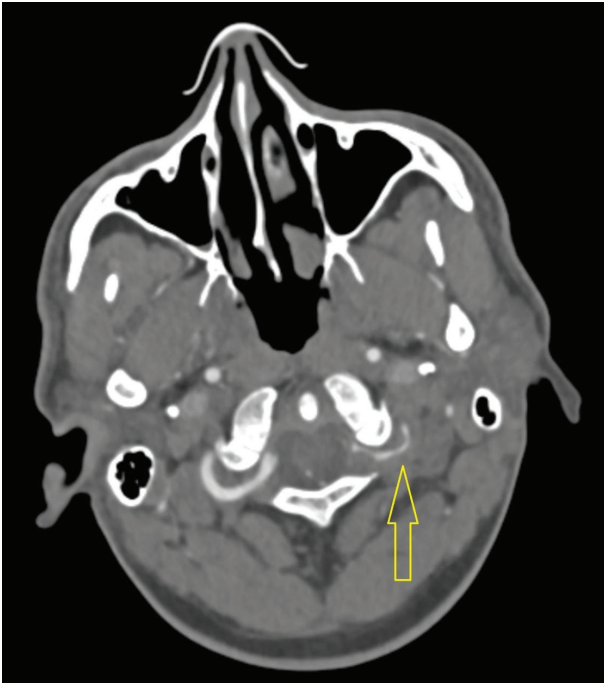

Figure 1. CT angiogram showing left vertebral artery narrowing and dissection.

Romberg's test, but the rest of the cerebellar examination was unremarkable.

CT head without contrast was performed initially, followed by a CT angiogram of the head which showed extradural narrowing and dissection of the left vertebral artery (Figure 1).

There was difficulty in getting an urgent report for the patient as the radiologist on call required further assistance from a specialist neuro radiologist for the final reporting of the CT scans.

The decision was made upon the advice of the radiology team to proceed with an MRI and MRA head and neck scan afterward which demonstrated dissection of the left vertebral artery. MR scan of the brain also showed left posterior inferior cerebellar artery territory infarcts with micro hemorrhages (Figure 2).

The final diagnosis of vertebral artery stenosis, dissection, and posterior inferior cerebellar artery territory infraction was confirmed after a series of CT angiograms in ED and an MRI/MRA head and neck scan the next day (Figure 3).

Symptomatic treatment with prochlorperazine, betahistine, and intravenous fluids in the emergency department did not help with the patient's symptoms. However, a single dose of Ondansetron was further prescribed which helped with severe dizziness and vomiting. The patient was admitted to the neurology ward after initial management in the emergency department. The next day MRI/MRA scan of the head and neck was performed and the patient was started on dual antiplatelet medications by the neurologist, which was continued for 6 months with a follow-up MRI/MRA scan of the head and neck.

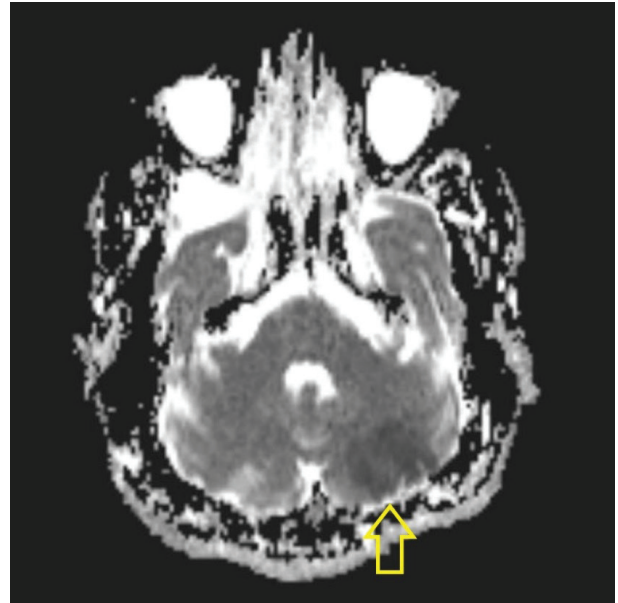


Figure 2. MR scan of the brain showing left posterior inferior cerebellar artery territory infarction.

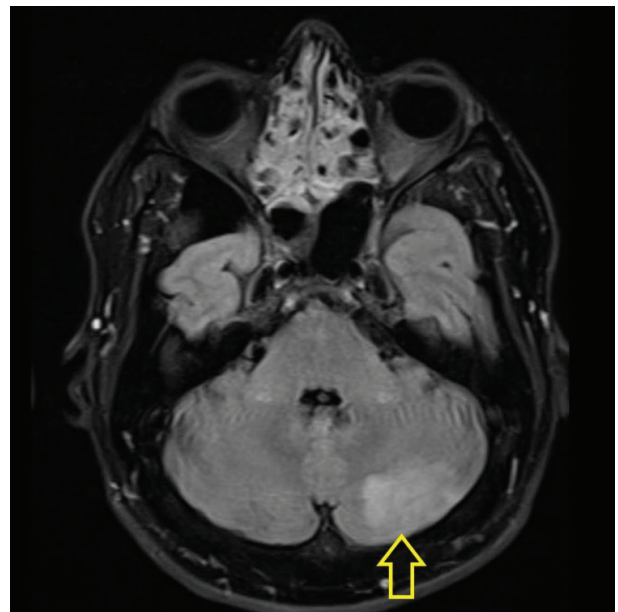


Figure 3. MR scan.

A further follow-up MRI/MRA head and neck scan was arranged six months after the initial findings, which showed that the old infarct of the left cerebellum had decreased in size. The repeat scan also mentioned the unchanged moderate stenosis of 30%–50% noted in the mid segment of the left vertebral artery. The patient continues to suffer from dizziness with sudden head movements, brisk walking, and running. With a conservative management plan, he was followed up by the neurology team in six months' time with a repeat MRI/MRA scan. The repeat scan findings of persistent stenosis in the left vertebral artery were discussed in a neurology multidisciplinary team meeting (MDT). Due to not enough evidence available for the management of such cases, a follow-up plan of repeat scans in another

six months was put in place. The patient was prescribed aspirin 75 mg daily until a repeat scan was performed.

Discussion

There is enough evidence in published literature, to suggest that the annual incidence of spontaneous vertebral artery dissection is 1–1.5 per 100,000. This number is almost half of the carotid artery dissection incidence, which stands at 2.5 to 3 per 100,000 [1]. It is noteworthy that dissections account for only 2% of all ischemic strokes [2], but a very important factor in the young ones and account for 20% of all strokes in patients less than forty five years of age [3].

Similarly, in the presented case report, the vertebral artery dissection resulted in a posterior inferior cerebellar stroke in a young patient without any previous background medical problems. It is also a fact that in the younger population, vertebral artery dissection can be clinically challenging due to its diverse presentation.

There is limited evidence to suggest if there are screening tools or guidelines available to be used by doctors to help in the diagnosis and management of vertebral artery dissection in the emergency department. In the presented case, a similar problem was encountered which was to formulate a definite management plan for the patient due to lack of available guidelines.

An MDT was arranged to agree on long-term management in the presented case. Early anticoagulation should ideally be the treatment in stroke patients; however, in traumatic injuries, it is seldom used. Certain factors play an important role in the better outcomes of patients with posterior circulation stroke, which include young age and ischemic strokes [9,10].

Following up on the presented case, it was noted that the patient was gradually improving, and symptoms were becoming less troublesome over time. However, it is still not clear if the patient would be able to return to his previous lifestyle before having the stroke.

Conclusion

This case report highlighted the importance of considering vertebral artery dissection for severe sudden onset central vertigo in a young patient during recreational sports where sudden neck movements are expected (in this case bowling). Nevertheless, it is vital to be aware of sports-related presentations resulting in sudden neck movements and tears in the vertebral artery causing dissection, where a history of neck pain/stiffness with severe vertigo should raise suspicions of vertebral artery dissection and subsequent radiological imaging of head and neck should be considered early in the management of such cases. Furthermore, posterior inferior cerebellar infarction has significant limitations on the quality of life. It can impair a patient's ability to participate in exercise

and sports which might have a negative effect on the long-term mental and physical health of the patient.

Conflict of interest

There is no conflict of interest regarding the publication of this case report.

Funding

None.

Consent for publication

Informed consent was obtained from the participant.

Ethical Approval

Ethical approval is not required at our institute for an anonymous case report.

Author details

Waseem Hassan¹, Asif Naveed¹

1. Walsall Healthcare NHS Trust, Walsall, UK

References

1. Kratz SN, Butler KH. Vertebral artery dissection presenting as acute cerebrovascular accident. *J Emerg Med.* 2011;40:151–7. <https://doi.org/10.1016/j.jemermed.2007.11.039>
2. Schievink WI. Spontaneous dissection of the carotid and vertebral arteries. *New England J Med.* 2001;22:898–906. <https://doi.org/10.1056/NEJM200103223441206>
3. Redekop GJ. Extracranial carotid and vertebral artery dissection: a review. *Can J Neurol Sci.* 2008;35:146–52. <https://doi.org/10.1017/S0317167100008556>
4. Wachal K, Koczewski P, Gabriel M, Kociemba W. Isolated internal carotid artery dissection in a longdistance runner. *Wideochir Inne Tech Maloinwazyjne.* 2016;304–308. <https://doi.org/10.5114/wiitm.2016.64449>
5. Engelter ST, Traenka C, Grond-Ginsbach C. Cervical artery dissection and sports. *Front Neurol.* 2021;31:663830. <https://doi.org/10.3389/fneur.2021.663830>
6. Desouza RM, Crocker MJ, Haliasos N. Blunt traumatic vertebral artery injury: a clinical review. *Euro Spine J.* 2011;20:1405–16. <https://doi.org/10.1007/s00586-011-1862-y>
7. Acharya V, Chandrasekaran S, Nair S. An interesting case report of vertebral artery dissection following polytrauma. *Int J Surg Case Rep.* 2016;28:196–99. <https://doi.org/10.1016/j.ijscr.2016.09.055>
8. Dunay SN, Perreault MD, Grubish LK. A case of delayed traumatic vertebral artery dissection. *Mil. Med.* 2018;183:276–7. <https://doi.org/10.1093/milmed/usx096>
9. Arnold M, Bousser MG, Fahrni G. Vertebral artery dissection presenting findings and predictors of outcome. *Stroke.* 2006;37:2499–503. <https://doi.org/10.1161/01.STR.0000240493.88473.39>
10. Sonia B, Grassi M., Zedde M. Italian project on stroke in young adults—cervical artery dissection 5 of 6 (IPSY CeAD) Research Group. Long-term outcome of cervical artery dissection: IPSY CeAD: study protocol, rationale, and baseline data of an Italian multicenter research collaboration. *Neurol Sci.* 2020;41:3265–72. <https://doi.org/10.1007/s10072-020-04464-9>